

CASE REPORT

Open Access



Syncopal storm in an elderly patient: unraveling the mechanism—a case report

Soorampally Vijay^{1*} , Ansul Patodia² and Yash Lokhandwala²

Abstract

Background Multiple episodes of syncope in rapid succession are extremely rare, and syncope in the elderly has multiple potential mechanisms. Even though the electrophysiology study has little role in patients with syncope who have structurally normal hearts, the history of syncope preceded by palpitations was a red-flag symptom that made us go ahead with the electrophysiology study (EP) that revealed the ultimate diagnosis of typical atrioventricular nodal reentry tachycardia (AVNRT), which was documented to be associated with critical hypotension.

Case presentation A 78-year-old man with a history of hypertension experienced a ‘Syncopal Storm,’ with four episodes within 15 min. There was no history to suggest common etiologies like postural hypotension or vasovagal syncope. The examination, ECG, and echocardiogram were normal. In view of the nasty sequence and a history of syncope preceded by palpitations, we conducted an electrophysiology study. Surprisingly, typical AVNRT at 190 bpm was easily and repeatedly induced with atrial extrastimuli. During the AVNRT, the systolic BP fell from 160 to 40 mm Hg with the development of presyncope. No ventricular tachycardia was inducible despite vigorous ventricular stimulation protocol. Radiofrequency ablation was performed successfully. The patient was symptom-free after 6 months of follow-up.

Conclusion We report a unique case of a syncopal storm due to AVNRT in the setting of a structurally normal heart. The syncopal storm is a rare but ominous presentation of AVNRT. The cause of syncope was a combination of a high heart rate, loss of atrioventricular synchrony, and an impaired autonomic vasomotor response, causing severe hypotension.

Keywords Supraventricular tachycardia, Syncope, Hypotension

Introduction

Typical AVNRT is the most common clinically relevant supraventricular tachycardia. Patients with AVNRT usually present with palpitations, shortness of breath, or lightheadedness. Although several case studies reporting syncope in the context of AVNRT with other comorbid conditions such as long QT syndrome, hypertrophic

cardiomyopathy, and an enlarged aorta compressing the right atrium resulting in underfilling of the right ventricle during the AVNRT have been published [1–4], the syncope secondary to AVNRT with a structurally normal heart is uncommon [5]. Previous reports suggest that compared to young, elderly patients had more syncope or presyncope episodes with AVNRT, likely due to frailty and the high prevalence of organic heart disease [6]. In this report, we present a rare case of an elderly patient who experienced a syncopal storm, due to typical AVNRT, which was documented to be associated with profound hypotension in the absence of structural heart disease.

*Correspondence:

Soorampally Vijay
surampallivijay8@gmail.com

¹ Department of Cardiology, Manipal Hospital, 98, HAL Old Airport Rd, Kodihalli, Bangalore, Karnataka 560017, India

² Department of Cardiology, Holy Family Hospital, Mumbai, India



© The Author(s) 2023. **Open Access** This article is licensed under a Creative Commons Attribution 4.0 International License, which permits use, sharing, adaptation, distribution and reproduction in any medium or format, as long as you give appropriate credit to the original author(s) and the source, provide a link to the Creative Commons licence, and indicate if changes were made. The images or other third party material in this article are included in the article's Creative Commons licence, unless indicated otherwise in a credit line to the material. If material is not included in the article's Creative Commons licence and your intended use is not permitted by statutory regulation or exceeds the permitted use, you will need to obtain permission directly from the copyright holder. To view a copy of this licence, visit <http://creativecommons.org/licenses/by/4.0/>.

Case details

A 78-year-old man presented with four episodes of syncope within 15 min on the same day, all of which were captured by closed-circuit television (Fig. 1). The first episode was while he sat in the compound of his building. He fell back, and fortunately, his head landed on a grassy patch. He decided to go up to his apartment. As he stood outside the elevator, he abruptly fell back, his head narrowly missing the concrete wall. Inside the elevator, he awkwardly crumpled down to the floor, fortunately without major injury. As he got out of the elevator, he again fell (Additional file 1: Videos 1–4).

He had a history of hypertension and was on amlodipine. On enquiry, syncope was sometimes preceded by palpitations. The physical examination was unremarkable, without orthostatic hypotension or carotid hypersensitivity. The ECG was unremarkable. Echocardiography revealed a structurally normal heart. A 24-h Holter showed few monomorphic premature ventricular complexes, with one ventricular triplet; there was no pause or bradycardia. The exercise stress test was negative for inducible ischemia. Magnetic resonance imaging with angiography of the brain was normal.

What is the next step?

There was a diagnostic dilemma in this case about whether to proceed with an implantable loop recorder (ILR) or an electrophysiological study. In view of the nasty episodes, it was risky to wait for yet another fall. Because the syncope event had high-risk features and sudden brief palpitations preceded syncope, it was determined that an EP study rather than an ILR would be appropriate in this case. The baseline AH and HV intervals were normal. Surprisingly, typical AVNRT at 190 bpm was easily and repeatedly induced with atrial extra stimuli. During the AVNRT, the systolic BP fell from 160 to 40 mm Hg with the development of presyncope (Fig. 2). The tachycardia was terminable with atrial extrastimuli and with ventricular overdrive pacing. Despite vigorously programmed ventricular stimulation procedures from two right ventricular locations, introducing up to three extrastimuli, and using short–long–short sequences, no ventricular tachyarrhythmia was induced. The slow pathway was successfully modified with radiofrequency ablation. Post-procedure, no more tachycardia was inducible, and at a 6-month follow-up, the patient was asymptomatic.

Discussion

AVNRT is the most common supraventricular tachycardia. Patients with AVNRT most commonly present with palpitations, sweating, dyspnea, and lightheadedness.



Fig. 1 Four falls. Left upper panel, sitting in the compound. Right upper panel, waiting for the elevator. Left lower panel, inside the elevator. Right lower panel, while leaving the elevator

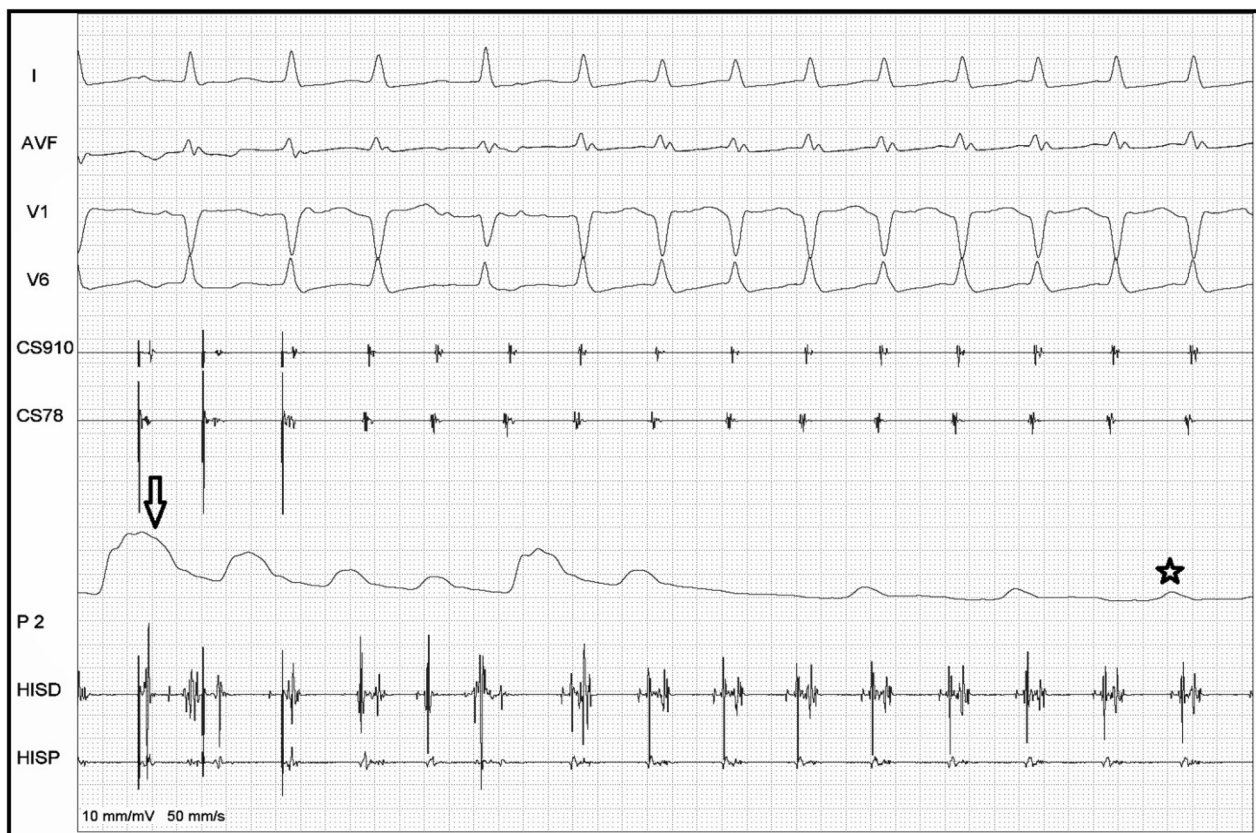


Fig. 2 During the tachycardia, the systolic BP dropped from 160 mm Hg (arrow) to less than 40 mm Hg (star) with the development of presyncope

A sensation of ‘neck pounding’ is one of the characteristic symptoms of typical AVNRT, due to atrial contraction against the closed tricuspid valve, causing rhythmic abrupt rises in venous pressure, also known as the ‘frog sign.’ Some patients with AVNRT experience diuresis during or after the tachycardia; the mechanism is probably related to an elevated mean right atrial pressure and plasma level of the atrial natriuretic peptide during the arrhythmia. Syncope is an uncommon but ominous presentation of AVNRT. In a study of 167 patients with supraventricular tachycardia who were referred for radiofrequency ablation, 64 had AVNRT; the most common symptom was palpitation (98%), while syncope was the least common (16%) [5].

It was initially thought that a heart rate ≥ 170 beats per minute was the only independent risk factor for syncope. However, this has been contested due to the lack of correlation between reported syncope and tachycardia cycle length [7, 8]. Syncope in AVNRT is more likely to occur at the onset of the arrhythmia due to sudden atrial distention and vigorous contraction against closed AV valves during AVNRT, leading to a strong reflexogenic stimulus resulting in impaired vasomotor function with delayed vasoconstrictive compensation resulting in syncope [9].

In some cases, the cause may be due to neurally mediated (neurocardiogenic) responses rather than a direct result of the tachycardia. In others, concomitant drug therapy (e.g., vasodilators) may undermine the compensatory vascular response [10]. In our case, syncope was likely due to a high heart rate, loss of atrioventricular synchrony, and an impaired autonomic vasomotor response, leading to cerebral hypoperfusion.

In our patient, the syncopal storm with four episodes in quick succession was exceptional. Either he developed recurrent episodes of AVNRT, or it was one prolonged episode with recurrent severe hypotension.

Conclusions

The syncopal storm is a very uncommon presentation of a common arrhythmia (typical AVNRT) in clinical practice. Multiple episodes of syncope in rapid succession are very rare. In most instances, patients will either be in a serious state or will be resting after an episode or two. Our patient, with a structurally normal heart, kept recovering well after every episode to be able to walk till the next episode. Finally, the culprit was AVNRT, which was documented to be associated with critical hypotension.

After successful ablation, the patient was asymptomatic at intermediate-term follow-up.

Abbreviations

AVNRT	Atrioventricular nodal reentry tachycardia
ECG	Electrocardiogram
EP	Electrophysiology

Supplementary Information

The online version contains supplementary material available at <https://doi.org/10.1186/s42444-023-00094-2>.

Additional file 1. Videos depicting four syncopal episodes.

Acknowledgements

BGC and PK, Cardiac Catheterization Laboratory, Holy Family Hospital, Mumbai.

Author contributions

SV involved in writing and revision, AP involved in revision, and YL involved in writing and revision. All authors read and approved the final manuscript.

Funding

Not applicable.

Availability of data and materials

Not applicable.

Declarations

Ethical approval and consent to participate

Not applicable.

Consent for publication

The patient's consent for publication was obtained.

Competing interests

The authors have no competing interests to declare.

Received: 10 January 2023 Accepted: 9 May 2023

Published online: 12 May 2023

References

- Horlitz M, Schley P, Marx R, Klein M, Bufe A, Lapp H, et al. Recurrent syncope in a young patient with long QT syndrome: possible relationship of atrioventricular nodal re-entrant tachycardia with neurally mediated spells? *Wien Med Wochenschr.* 2003;153(1–2):46–8.
- Ebrille E, Contreras-Valdes FM, Zimetbaum PJ. Hemodynamic response to supraventricular tachycardia in a patient with hypertrophic cardiomyopathy. *Heart Rhythm Case Rep.* 2019;5(4):191–5.
- Yagi M, Konno T, Nagata Y, Fhjino N, Hayashi K, Kawajiri M, et al. Atrioventricular node reentrant tachycardia as a cause of recurrent syncope in a patient with non-obstructive hypertrophic cardiomyopathy. *J Card Fail.* 2014;20:S196–7.
- Lee PJ, Varosy P, Sandhu A. Uncommon presentation of a common disorder: syncope with AVNRT in setting of a structural anomaly. *Clin Case Rep.* 2020;8(3):477–80.
- Wood KA, Drew BJ, Scheinman MM. Frequency of disabling symptoms in supraventricular tachycardia. *Am J Cardiol.* 1997;79:145–9.
- Kalusche D, Ott P, Arentz T, Stockinger J, Betz P, Roskamm H. AV nodal re-entry tachycardia in elderly patients: clinical presentation and results of radiofrequency catheter ablation therapy. *Coron Artery Dis.* 1998;9(6):359–63.

- Leitch JW, Klein GJ, Yee R, Leather RA, Kim YH. Syncope associated with supraventricular tachycardia. An expression of tachycardia rate or vaso-motor response? *Circulation.* 1992;85(3):1064–71.
- Kavthale SS, Vajifdar BU, Naik AM, Vora AM, Lokhandwala YY. Age at onset, gender distribution and intraarterial blood pressure changes in atrioventricular node-dependant tachycardias. *J Assoc Physicians India.* 1999;47(4):373–6.
- Razavi M, Luria DM, Jahangir A, Hodge DO, Low PA, Shen WK. Acute blood pressure changes after the onset of atrioventricular nodal reentrant tachycardia: a time-course analysis. *J Cardiovasc Electrophysiol.* 2005;16(10):1037–40.
- Doi A, Miyamoto K, Uno K, Nakata T, Tsuchihashi K, Shimamoto K. Studies on hemodynamic instability in paroxysmal supraventricular tachycardia: noninvasive evaluations by head-up tilt testing and power spectrum analysis on electrocardiographic RR variation. *Pacing Clin Electrophysiol.* 2000;23:1623–31.

Publisher's Note

Springer Nature remains neutral with regard to jurisdictional claims in published maps and institutional affiliations.

Ready to submit your research? Choose BMC and benefit from:

- fast, convenient online submission
- thorough peer review by experienced researchers in your field
- rapid publication on acceptance
- support for research data, including large and complex data types
- gold Open Access which fosters wider collaboration and increased citations
- maximum visibility for your research: over 100M website views per year

At BMC, research is always in progress.

Learn more biomedcentral.com/submissions

